



# **Large C5-6 Left Paracentral Disc Herniation with Cord Impingement Treated Conservatively with Cox® Cervical Flexion-Distraction Decompression Technic**

submitted by  
Larry F. Widmer, DC, DACO  
May 21, 2015

## **Introduction**

Conservative care produces successful outcomes for cervical disc herniations. One research report states that patients with neck pain with or without radiculopathy or myelopathy show no difference in clinical outcomes of surgical and conservative treatment. (1) Another report describes better responses to conservative care than surgical treatment in neck and radicular pain patients without myelopathy. (2) Further, in one clinical report, flexion distraction treatment relieved pain in a 51 year old woman who suffered with left arm pain for 2 years prior to this care. She reported relief after the first treatment and total relief in 24 visits in 6 months. (3) Another report shows relief of a C6-7 disc herniation, foraminal narrowing and associated radiating pain and radiculopathy in the left upper extremity. (4) In a larger clinical data study of 39 patients with cervical radiculopathy treated with flexion distraction, the VAS scores dropped from 50.1 to 8.7. (5) In recent chiropractic biomechanical research, cervical spine flexion distraction protocols lower C4-C7 levels intradiscal pressures from 96-1583 mmHG pressure depending on the level and protocol used. (6) Lastly, research studies into the proper application of flexion distraction to the cervical spine for such conditions as disc herniation reveal that physicians can apply the prescribed forces to the cervical spine 97% of the time using a visual feedback system. (7) Proper application allows for better reproduction of research reported outcomes clinically as seen in this case report.

## **Abstract**

A 40 year old female patient presented to a chiropractic clinic with a large C5-6 left paracentral disc herniation with cord compression and associated moderate to severe left and moderate right-sided neural foraminal narrowing at the same level. Cox® Cervical Flexion-Distraction Decompression Technic was utilized to successfully manage the case.

## **History**

A 40 year old female presented to our chiropractic clinic with an insidious onset of pain in her neck, left arm and scapular region. Her symptoms began about a week prior to

presentation. She attempted to self medicate with Advil and hydrocodone which did not give relief. Patient has had a history of cervical disc herniation. She stated that her left upper extremity pain was more prevalent than her neck pain and had had great difficulty sleeping as a result.

### Examination

On examination the patient was alert and oriented x3. She had normal hearing, speech and facial expressions. There were no skin rashes or lesions noted. There was no lymphadenopathy and the trachea was midline. There was no respiratory distress. There were no carotid bruits, cyanosis, clubbing or edema noted.

There was tenderness to palpation in the left cervical paraspinals as well as the left upper thoracic spine. The upper extremity myotomes were 5/5. Reflexes of the upper extremities were 2/4 with sensation intact to light touch. Hoffman's was negative. Foraminal compression caused left sided scapular pain. Cervical distraction gave relief of the extremity symptoms. Cervical range of motion was decreased by 40% in all planes.

Subjectively, she reports a VAS of 9 out of 10 on the date of the first treatment.

### Imaging

MRI of the cervical spine revealed a large C5-C6 left paracentral disc protrusion that was altering the contour of the left anterior spinal cord with associated cord flattening. There was no obvious cord edema. There was associated moderate to severe left and moderate right-sided neural foraminal narrowing at that level.

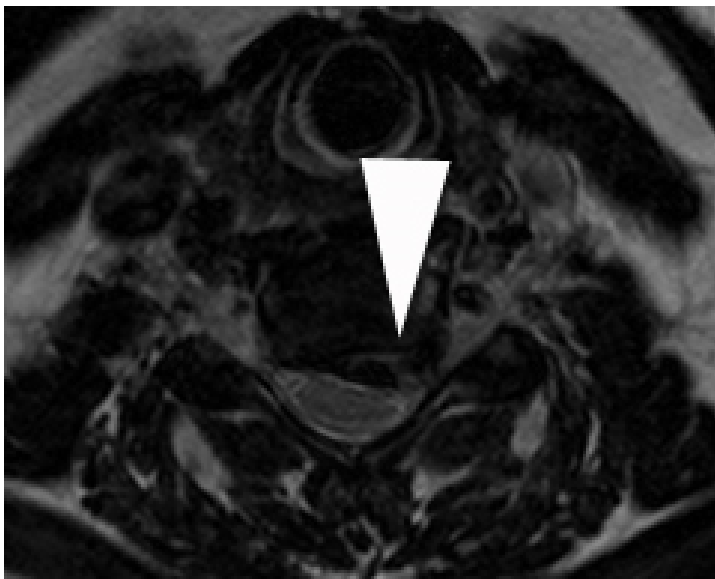


Figure 1. A large C5-C6 left paracentral and intraforaminal disc herniation is seen that deforms the spinal cord and reveals severe neural and intraforaminal stenosis. (See arrow.) Also note the hyperintense inflammatory process within the annulus that extends through a rent in the annulus fibrosus extending into the osseoligamentous canal.

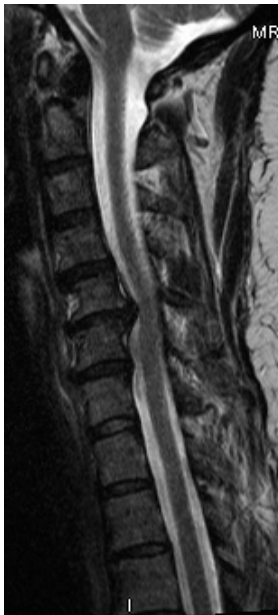

Figure 2. Sagittal view shows retrolisthesis of C5 on C6 with the large disc herniation as seen on axial view in Figure 1. The spinal cord is contacted by the herniated disc

## Treatment

Treatment consisted of Cox® Cervical Flexion-Distraction Decompression Technic using Protocol 1 at a frequency of 3 visits per week for the first two weeks. Protocol 1 is used for gentle specific level treatment in patients who have radiculopathy, in this case such that extends below the elbow. In Protocol 1, the physician grasps the spinous process of the vertebra above the herniation, in this case C5, and decompresses the C5-6 segment using the long-y feature of The Cox®8 Table. (See Figures 3 and 4.) Ultrasound was applied in office. The patient was asked to use ice applications for about 15 minutes every hour or two. She was instructed to maintain neutral spine postures for all activities of daily living. She also used a home traction unit with 10 pound weight when she had significant discomfort at home.

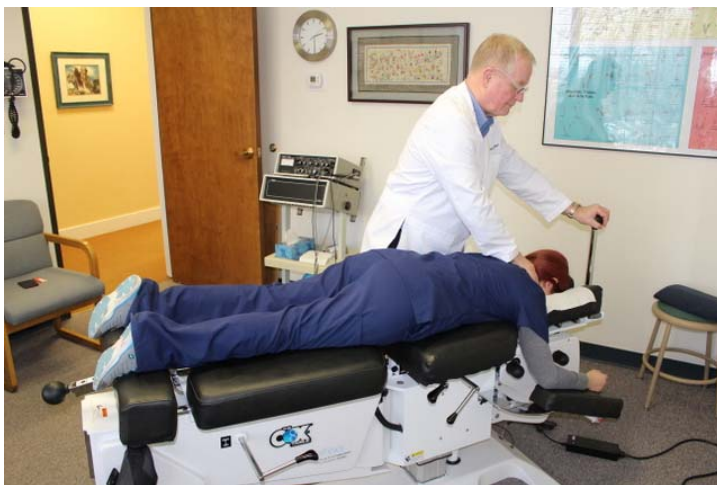

Figure 3. Cox Technic long-y axis decompression spinal manipulation is applied to the C5-6 segment.

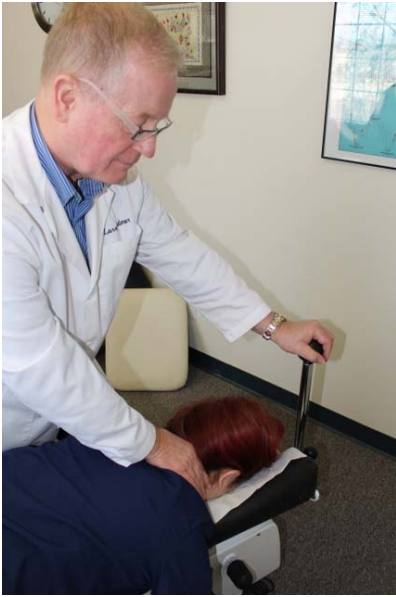

Figure 4. Close up of contact.

### **Outcome**

First, please note that this patient has had two similar prior episodes and had been treated successfully with Cox® Technic in each episode.

Now, in this episode, by her third treatment on December 1, 2014, she stated that she was feeling much better with the pain localizing primarily to the left upper thoracic spine. By her December 8, 2014 visit the numbness in her left thumb would come and go. On her 10<sup>th</sup> treatment on December 22, 2014, she reported that she was feeling better with a VAS score of 3/10. She was discharged from active care after her 18<sup>th</sup> treatment with no significant pain or discomfort.

### **Conclusion**

This 40 year old female patient with a large C5-6 paracentral disc herniation with cord flattening and moderate to severe left neural foraminal narrowing was successfully treated conservatively utilizing the Cox® Technic cervical flexion-distraction decompression system.

### **Closing Comment**

Specifically applied flexion distraction to the cervical spine continues to grow in research-documented outcomes for both biomechanical and clinical outcomes that result in patient satisfaction as this patient experienced.



## Byline

The featured case report is by Larry F. Widmer, DC, DACO, a Cox® Technic certified physician currently practicing in Santa Fe, NM. This case was one of his when he practiced in Lancaster, PA.

## References:

1. van Middelkoop M, Rubinstein SM, Ostelo R, van Tulder MW, Peul W, Koes BW, Verhagen AP: Surgery versus conservative care for neck pain: a systematic review. *European Spine Journal* 2013;22(1):87-95.
2. Heckmann JG, Lang CJ, Zöbelein I, Laumer R, Druschky A, Neundörfer B. Herniated cervical intervertebral discs with radiculopathy: an outcome study of conservatively or surgically treated patients. *J Spinal Disord.* 1999 Oct;12(5):396-401.
3. Kruse RA, Imbarlina F, DeBono VF: Treatment of cervical radiculopathy with flexion distraction. *J Manipulative Physiological Therapeutics* 2001;24(3):206-209.
4. Manison, Allen M. Chiropractic Management Using Cox Cervical Flexion-Distracton Technique for a Disk Herniation with Left Foraminal Narrowing in a 64-Year-Old Man. *Journal of Chiropractic Medicine* 2011; 10(4): 316–321.
5. Schliesser JS, Kruse RA, Fleming Fallon L: Cervical radiculopathy treated with chiropractic flexion distraction manipulation: a retrospective study in a private practice setting: *Journal Of Manipulative And Physiological Therapeutics* 2003;26(9):592-596
6. Gudavalli R, Potluri T, Caranandang G, Havey R, Vornov L, Cox J, Rowell R , Kruse R, Joachim G, Patwardhan A, Henderson, Goertz: Intradiscal Pressure Changes during Manual Cervical Distraction: A Cadaveric Study. *Evidence-Based Complementary and Alternative Medicine Volume 2013 (2013)*, Article ID 954134, 10 pages <http://dx.doi.org/10.1155/2013/954134>
7. Gudavalli MR et al. Clinician proficiency in delivering manual treatment for neck pain within specified force ranges. *The Spine Journal* 2015; 15(4): 570 – 576.