

# Calcified L5-S1 Disc Herniation with Radiculopathy: A Case Report

Dean Greenwood DC, MS, FACO, FCCO  
Vancouver Spine Care Centre  
Vancouver, BC

Presented at the Cox® Part 3 Seminar, March 21-22  
Las Vegas, Nevada

## History and Chief Complaint

- 44 y/o female consultant and mother
- Constant left lower back, hip and leg pain
- 8/10 VNS
- 3 months duration
- Insidious onset
- Pain is worse with walking, coughing, sneezing and rolling over
- OTC anti inflammation and pain meds provided minimal relief
- Similar episode 4 year prior but not as severe
- Hyperextension lumbar spine injury 25 years prior

## Exam

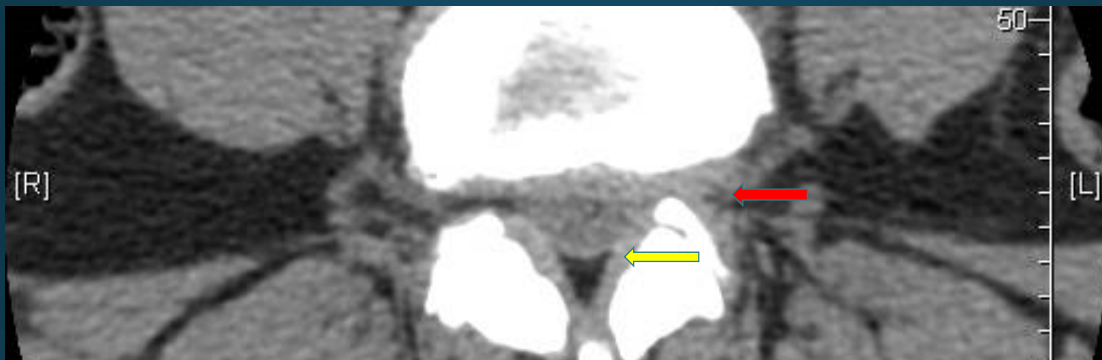
- Patient is antalgic to right side and in obvious distress
- Gait is slow and transitions are difficult
- Left lateral lumbar flexion is too painful to attempt
- Lumbar ROM is severely impaired due to guarding in all directions
- SLR + on left leg at 45 degrees with pain to left gluteal and left lateral calf; SLR – on right leg at 90 degrees
- Left Achilles DTR 0, right Achilles +2. L&R patellar and hamstring DTR +2
- Left leg is cold to the touch compared to right. Pedal pulses are present but diminished compared to right
- Painful, palpable trigger points in left gluteal and left calf
- Dejerines Triad present

## Exam cont.

- Dorsi flexion, plantar flexion 5/5 bilaterally
- Inversion and eversion 5/5 bilaterally
- Quads, hamstrings and hip flexors 5/5 bilaterally
- Patrick's test negative bilaterally
- Babinski is absent bilaterally
- Light touch sensation is preserved in both legs and feet

# Imaging

- CT scan done 1 week prior to examination and is compared with scan done June 25, 2010
- Report provided by patient at intake
- “L4-5 moderate narrowing of the disc space is now present. A generalized bulge of the IVD has worsened. This is asymmetrically more prominent in the left posterolateral through foraminal region. This causes moderate narrowing of the left neural foramen potentially irritating the left L4 nerve root. Crowding in the left lateral recess could irritate the traversing left L5 nerve root.”

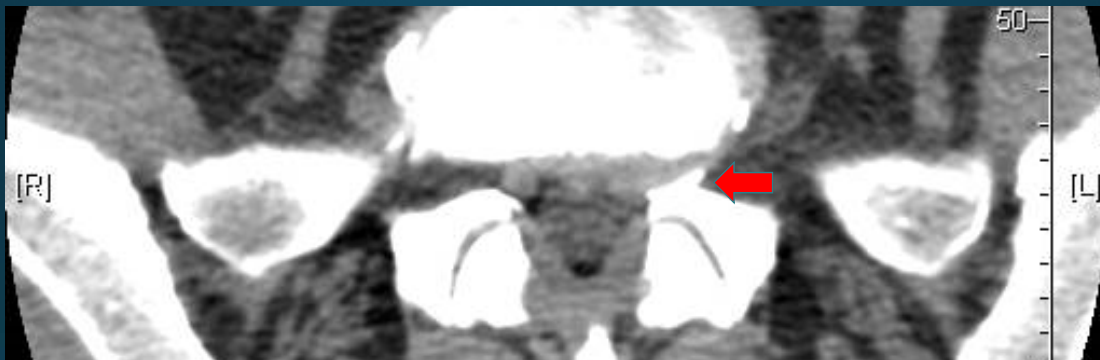

## Axial CT of L4-5

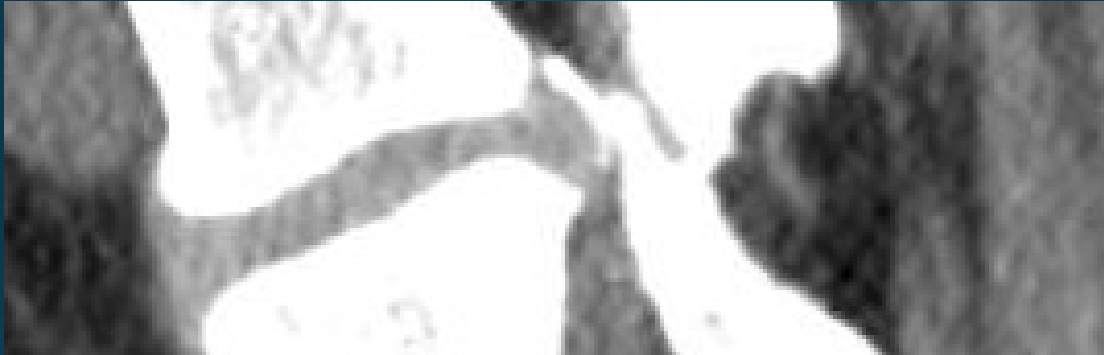Thickening of the **Ligamentum Flavum** and central canal stenosis not reported.

## Imaging cont.

- “L5-S1 moderate loss of disc space height is again identified. A generalized bulge of the IVD is again identified, asymmetrically more prominent in the left posterolateral through foraminal region. This portion of the disc has now *calcified*. Mild narrowing of the left neural foramen without definite evidence of impingement of the exiting left L5 nerve root. Crowding in the left lateral recess causes posterior displacement and probable irritation of the traversing left S1 nerve root. Mild degenerative changes are present in the facet joints at these levels.”



Axial CT of L5-S1



Sagittal CT of L5

## Diagnosis

- Left intraforaminal calcified disc herniation at L5-S1 with associated radiculopathy in the S1 dermatome
- Left intraforaminal broad based disc bulge causing lateral canal stenosis

## Treatment

- Cox© Flexion Distraction Manipulation based on tolerance testing
- Protocol 1 until 50% relief or no lateralization during treatment
- Trigger point massage of left gluteal and calf muscles
- 3 X per week for 4 weeks
- Re-exam each visit
- Advise patient to monitor bladder, bowel and leg function
- Ice and heat alternating 3 times per day
- Disc Nutrition
- 10 low back exercises to tolerance
- Reduce sitting
- Reassurance

## Treatment cont.

- “If the patient has an antalgic list, place the caudal section of the table to match the list to aid in relief of pain and treatment efficacy.” (from Low Back Pain: Mechanism, Diagnosis and Treatment; Seventh Edition, page 370)
- Patient tolerated prone flexion distraction, axial decompression and right lateral flexion
- Cox© Instrument allows smooth, doctor controlled motion to give patient immediate relief
- LLF contraindicated

## Goals of Treatment

- 50% pain reduction within 4 weeks
- Prevent surgery
- Improve function for family holiday
- Re-Afferentation of left leg
- Monitor for signs of central canal stenosis
- Teach patient importance of good spinal hygiene for life

## Outcome

- Patient attended twice per week due to distance and schedule
- 6<sup>th</sup> visit patient relatively unchanged with no tolerance to LLF
- 7<sup>th</sup> visit patient reports less leg pain and improved function
- 8<sup>th</sup> visit patient reports no pain rolling in bed, 20 minutes of level walking, quicker recovery
- 10<sup>th</sup> visit patient reports leg pain reduced to 0/10 with mild persisting, localized left lower back pain and slight loss of proprioception in left leg
- Increased LLF tolerance to 15 degrees
- Holiday as scheduled with family
- No additional imaging planned, no surgical referral
- Care ongoing at reduced frequency

## Discussion

- Cox© Flexion Distraction Manipulation was shown to be very effective in the treatment of a calcified lumbar disc herniation with radiculopathy in this case
- Attention to imaging detail is important in appreciating the full pathophysiology of the degenerative process as it precedes annular bulges and the subsequent sequelae of morphologic changes

## Discussion cont.

- Additive factors such as adjacent disc herniations, ligamentum flavum thickening and central canal stenosis may worsen symptoms and complicate differential diagnosis
- Visualizing the images prior to commencing treatment was very useful in this case
- Long term management to minimize this patient's risk of spinal stenosis will be offered
- Additional research into the long term benefits of chiropractic care should be undertaken



**“Disc nucleus pulposus microscopic calcification is a common event occurring in adult patients suffering from lumbar disc herniation.** Mechanisms that link disc degeneration, angiogenesis, and calcification remain a focus for further research that may be useful in future medical treatments before surgical treatment of lumbar disc herniation.”

Frequency of lumbar intervertebral disc calcification and angiogenesis, and their correlation with clinical, surgical, and magnetic resonance imaging findings.

Karamouzian S<sup>1</sup>, Eskandary H, Faramarzee M, Saba M, Safizade H, Ghadipasha M, Malekpoor AR, Ohadi A.

Spine (Phila Pa 1976). 2010 Apr 15;35(8):881-6

**“Herniated and spondylotic intervertebral discs undergo different degenerative processes.** It is likely that TNF $\alpha$ , MMP-3, bFGF, and VEGF expression is upregulated via the herniated mass in the herniated IVD's, but by nutritional impairment in the spondylotic discs. **The herniated discs showed granulation tissue, newly developed blood vessels, and massive infiltration of CD68-positive macrophages, which surrounded the herniated tissue mainly in the ruptured outer layer of the annulus fibrosus.**”

Herniated and spondylotic intervertebral discs of the human cervical spine: histological and immunohistological findings in 500 en bloc surgical samples. Laboratory investigation.

Kokubo Y<sup>1</sup>, Uchida K, Kobayashi S, Yayama T, Sato R, Nakajima H, Takamura T, Mwaka E, Orwotho N, Bangirana A, Baba H.

J Neurosurg Spine. 2008 Sep;9(3):285-95.