



Manual Cervical Distraction: a Safe and Effective Treatment for Cervical Stenosis with Radiculopathy

by **Charles R. Portwood, DC***, **Matthew Budavich, BA****

*Dr. Portwood is a 1991 Graduate of Logan Chiropractic College and the attending chiropractic physician at Scott Air Force base

**Matthew Budavich is a National Universities of Health Sciences Trimester 9 intern at Scott Air Force base.

Introduction

Cervical radiculopathy is well managed with conservative treatment and the majority of patients improve with non-surgical management.¹ Controversy over the efficacy of active conservative treatment methods has been the cornerstone of debate for decades. While some advocate for Chiropractic treatment utilizing high-velocity, low-amplitude manipulation (HVLA) as an effective treatment for cervical radiculopathy², others see this treatment method as a contraindicated.³ Risk associated with cervical radiculopathy with stenosis are present with conservative treatment and surgical intervention.⁴ The goal of conservative treatment of cervical radiculopathy is to reduce radicular pain and weakness in the affected extremity and to avoid surgery. Surgery is reserved for patients who are resistant to multiple forms of conservative treatment who continue with progressive motor deficits and intractable pain.⁵ In this case report, we examine treatment of cervical radiculopathy with Cox® Technic Flexion Distraction [aka in research studies, Manual Cervical Distraction (MCD)] protocols for the cervical spine.⁶

History

A 38 year old female, known to the chiropractic clinic, presented on November 13, 2015, with an acute onset chronic exacerbation of severe neck, right upper back, right posterior lateral arm pain and a headache of five days duration. Her headache originated at the top of her head and the patient stated “my hair hurts.” She reported scintillation, but no scotoma. She denied photophonophobia, no dizziness, no nausea, and no numbness of the face, lips or tongue. Her pain radiated from the head caudally into the neck and mid thoracic spine on the right. She rated her neck pain and mid back pain as 5/10 on the Borg Scale. She stated, “The chiropractic adjustments always take the pain away and make my headaches go away, but this time it’s different.” She reported a new insidious onset of intermittent tingling in the right forearm, thumb and first finger along the C6 dermatome. She reported radiation of pain from the neck extending into the posterior lateral aspect of the right arm. She endorsed a “feeling of weakness” in the right upper extremity. She reported paresthesia in the C6 dermatome on the right.

Examination

Patient was in apparent distress moving her neck and upper back as one unit. Vital signs: Blood Pressure (BP) = 120/78 (left arm); Heart rate: 63; Respiration rate: 16; Temperature: 97.3 °F; Height: 60 in; Weight: 125 lbs.; BMI: 24.41. Patient presented with anterior head carriage, inferior migration of the shoulders bilaterally, and spasm of paracervical musculature. Cervical ROM decreased in right lateral flexion 30° and right/left rotation 65°/70° respectively. Lateral flexion on either side provoked pain at

end range. Positive cervical compression test for neck pain. Maximal foraminal compression test reproduced the patient's chief complaint of neck pain, pain into the right arm, and paresthesia in the right C6 dermatome. Distraction of the C/S palliated the patient's radicular symptoms. Decreased muscle strength graded as 4/5 in the brachioradialis on the right. Vertebral artery insufficiency tests were negative.

Treatment and Outcome

The patient was initially treated with HVLA adjustments of the C/T spine followed by ice and interferential therapy 80-120Hz for 20 minutes. She reported some palliation with pain and no significant increase in range of motion although her muscle strength on the right returned to normal. A three view cervical spine radiographic series was obtained to assess for discogenic spondylosis, facet arthrosis and hypertrophy of the Von Luschka joints as etiology for her radicular symptoms. Radiographs (Figure 1) revealed straightening of the normal cervical curve, marginal osteophyte formation and disc space narrowing at C5-6 and C6-7 levels and mild hypertrophy of the right C6 unciniate process.

On December 11, 2016, the patient contacted the clinic for an urgent appointment reporting neck, right upper back and right arm pain rated as 8/10. Her right upper back and arm pain were greater than her neck pain. She was unable to extend her neck or mid back without severe upper back pain with right posterior lateral arm pain. She was treated using spinal manipulation and reported minimal palliation but was able to return to work. Later that afternoon, the patient returned with increased neck pain, paresis and paresthesia in the C6 dermatome on the right noting her pain as intractable 10/10.

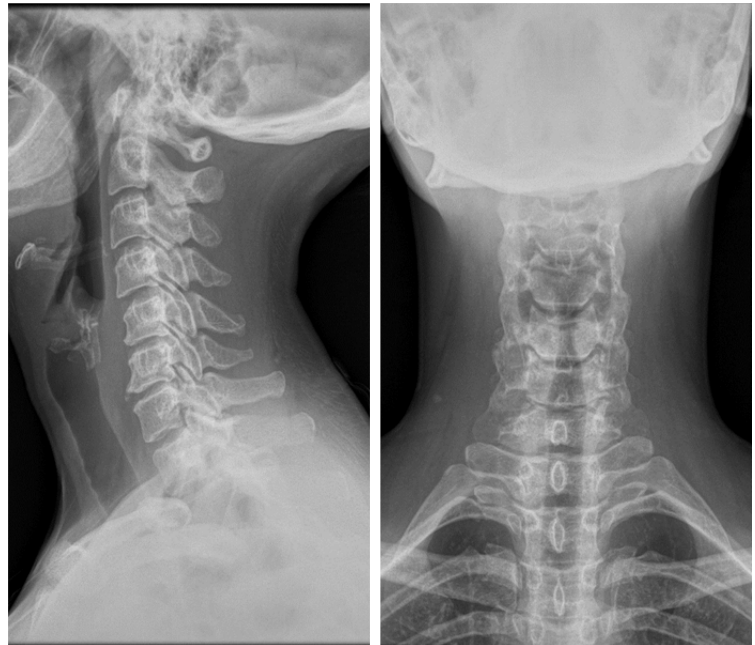


Figure 1

She was treated utilizing a form of chiropractic manipulation using a specially designed table that incorporates traction called manual cervical distraction (MCD), or flexion distraction, developed by Cox.⁷ Status post treatment the patient reported a 50% reduction in neck pain, upper back and right arm pain. She was prescribed home pneumatic traction to be performed 3-4 times daily to tolerance 12-15min per treatment. A cervical MRI was ordered to evaluate the integrity of the cervical disc at C5-C6.

The patient returned to the clinic four days later noting a 50% reduction in neck pain with intermittent radicular symptoms in the C6 dermatome of the right upper extremity with no paresis. Her neck pain

was more than her arm pain and she was able to perform her ADL's with minimum pain. She was treated with (MCD) directed at C5-C6 cervical segments.

Multiple MR sequences through the cervical spine were obtained on December 28, 2015 to include T2 sequences in the sagittal and axial plane. T1 sequences in the sagittal plane, T2 star fat saturated sequences in axial plane, and 3-D SSFP sequences in the axial plane. (Figures 2,3)

There is reversal of the normal cervical lordosis within the upper cervical spine. The cervical vertebrae are otherwise normal in alignment. Vertebral body and marrow signal is preserved. Vertebral body heights are normal. There is intervertebral disc height loss at C5-6 and C6-C7.

The cervical cord is normal in morphology and signal. No abnormal signal within the epidural space or thecal sac. The visualized posterior fossa has a normal MR appearance.

There are normal flow-voids within the carotid and vertebral arteries. No deep neck space mass or fluid collection. The visualized parotids are normal in appearances. The thyroid gland has a normal MR appearance. Prevertebral, paraspinal, and superficial soft tissues are likewise normal.

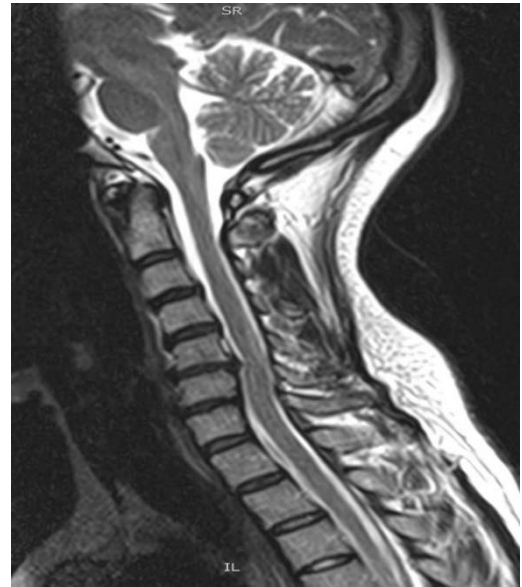

Figure 2

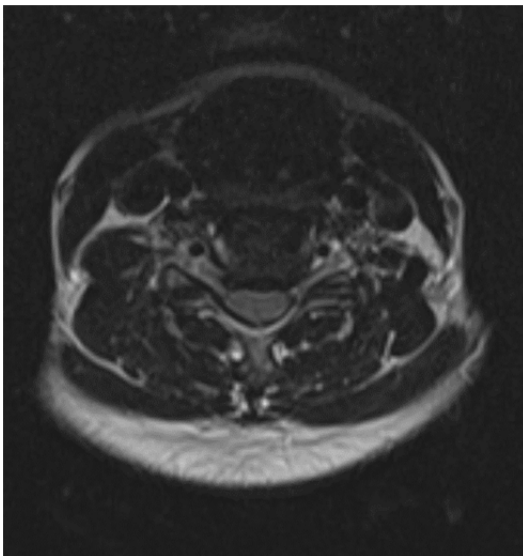


Figure 3

C2-3 No posterior disc bulge, central canal stenosis or neuroforaminal narrowing. No significant facet hypertrophy.

C3-4 No posterior disc bulge, central canal stenosis or neuroforaminal narrowing. No significant facet hypertrophy.

C4-5 There is a posterior disc osteophyte complex which effaces the ventral thecal sac and contacts the cervical cord at this level. There is resultant mild central canal stenosis. Mild to moderate right neuroforaminal narrowing is also present. The left neuroforamina is normal. No significant facet hypertrophy.

C5-C6 There is a posterior disc osteophyte complex which effaces the ventral thecal sac and contacts the cervical cord at this level. There is resultant mild central canal stenosis. Mild to moderate right neuroforaminal narrowing is also present. The left neuroforamina is normal. No significant facet hypertrophy.

Figure 3

C6-7 There is a small posterior disc osteophyte complex which effaces the ventral thecal sac but does not contact the cervical cord at this level. There is resultant mild central canal stenosis. Mild right and moderate left neuroforaminal narrowing is present. No significant facet hypertrophy.

C7-T1 No posterior disc bulge, central canal stenosis or neuroforaminal narrowing. No significant facet hypertrophy.

The patient returned to the clinic on December 29, 2015 and endorsed 1/10 neck pain, normal ROM stating, "The neck isn't hurting today, but I am getting this numbness and tingling in the right arm and thumb and the first finger on the right. It is constant." She denied paresis or radiation of pain this encounter. She was treated manual cervical distraction MCD noting centralization of her radicular symptoms.

January 11, 2016, she returned for her fifth treatment and reported 5/10 neck pain but with complete resolution of her radicular symptoms in the right upper. Manual cervical distraction MCD was performed and the patient noted near complete resolution of neck pain.

She was released from care and seeks treatment PRN-ER for exacerbation of neck and back pain.

Discussion

The patient was treated seven times with reduction of pain by 50% after the first treatment, restoration of cervical spine range of motion and complete resolution of radiculopathy after five treatments.

Clinical concerns related to manipulation of cervical spine in the presence of central stenosis include the development myelomalacia. As spinal stenosis progresses, the development of myelomalacia may result from restricting the blood supply to the spinal cord. The clinician must quickly identify stenotic patients and choose a treatment protocol that mitigates the risk of spinal cord degeneration and the development of pyramidal signs. While our patient did not have myelomalacia we discussed the potential risk and benefits of treatment in patients with mild to moderate cervical stenosis (Figure 4) prior to initiating treatment.

The normal adult male cervical canal is 17-18 mm in the upper cervical region and 12-14 mm in the lower cervical region. Cervical stenosis is associated with a canal measurement of less than 10 mm in anterior to posterior diameter. Causes of spinal stenosis vary from ligamentum flavum hypertrophy, bony spondylitic hypertrophy and a bulging disc annulus. Stenosis is graded as mild, moderate or severe, based on presentation of symptoms and roentgen findings. A severe diagnosis is associated with stenotic patients who were previously mild/moderate and no longer responding to conservative care

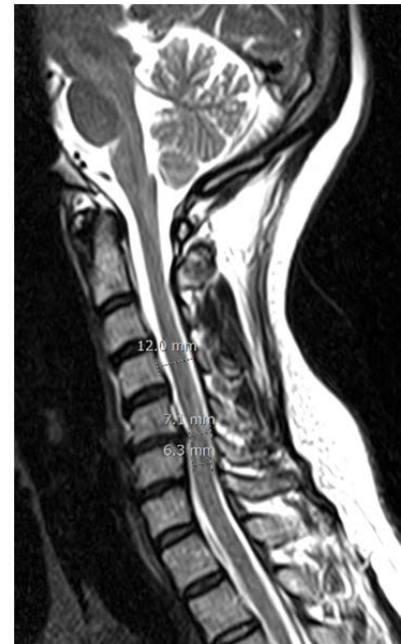

Figure 4



strategies.^{5,8} Severe spinal stenosis usually requires surgical intervention. Mild to moderate spinal stenosis is treated conventionally using a combination of anti-inflammatories, pain medications and cervical collars. Chiropractic Physicians can play a crucial role in helping the progression of cervical spinal stenosis.

Conclusion

Cox® MCD protocol for the cervical spine is an effective treatment for cervical radiculopathy. Even when radicular pain and sensation lost are complicated by central or foraminal stenosis, Cox® FD is a safe and powerful treatment. In a multi-provider clinic we found that every practitioner was able to achieve the same force outlined in the treatment protocol and subsequently the same clinical outcome. This inter-examiner reliability was achieved by the attending physician and by interns who engaged in the patient's treatment plan.

References

1. Sampath P, Bendebba M, Davis JD, Ducker T. Outcome in patients with cervical radiculopathy. Prospective, multicenter study with independent clinical review. *Spine (Phila Pa 1976)* 1999;24(6):591–597.
2. Beneliyahu DJ. Chiropractic management and manipulative therapy for MRI documented cervical disk herniation. *J Manipulative Physiol Ther.* 1994;17(3):177–185.
3. Fabio RP. Manipulation of the cervical spine: risks and benefits. *Phys Ther.* 1999;79(1):50–65.
4. A Clinical Practice Guideline Update from The CCA•CFCRB-CPG. *The Journal of the Canadian Chiropractic Association.* 2007;51(1):19-22.
5. Lees F, Turner JWA: Natural history and prognosis of cervical spondylosis. *BMJ* 1963;2:1607.
6. M. R. Gudavalli, T. Potluri, G. Carandang, et al., “Intradiscal Pressure Changes during Manual Cervical Distraction: A Cadaveric Study,” *Evidence-Based Complementary and Alternative Medicine*, vol. 2013, Article ID 954134, 10 pages, 2013.
7. J.M. Cox, *Neck, Shoulder, Arm Pain: Mechanism, Diagnosis, Treatment*, 3rd Edition, 2004.
8. Fujiwara K, et al: Morphometry of the cervical spinal canal and its relation to pathology in cases with compression myelopathy. *Spine* 1988;13:1212.
9. Cambron, J. A., Schneider, M., Dexheimer, J. M., Iannelli, G., Chang, M., Terhorst, L., & Cramer, G. D. (2014). A Pilot Randomized Controlled Trial of Flexion-Distraction Dosage for Chiropractic Treatment of Lumbar Spinal Stenosis. *Journal of Manipulative and Physiological Therapeutics*, 37(6), 396-406.