

C5-6 Disc Herniation with Radiculopathy & Instability Relieved with Cox[®] Decompression Adjustment & Manipulation

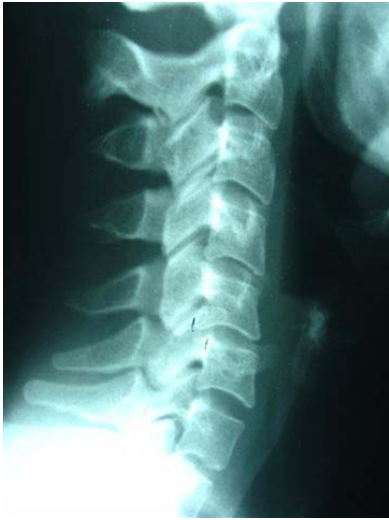

Figure 1

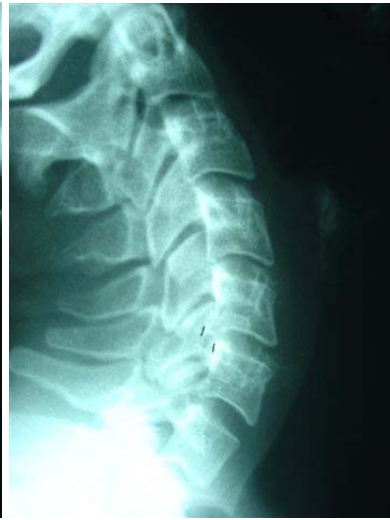

Figure 2

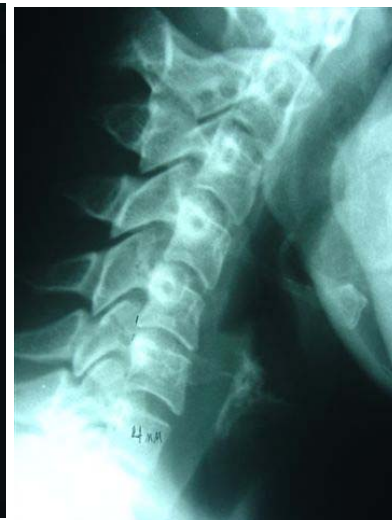

Figure 3

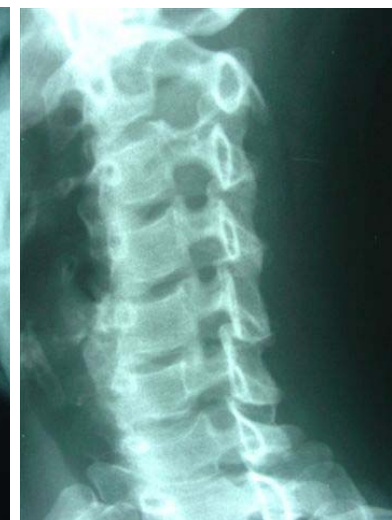

Figure 4

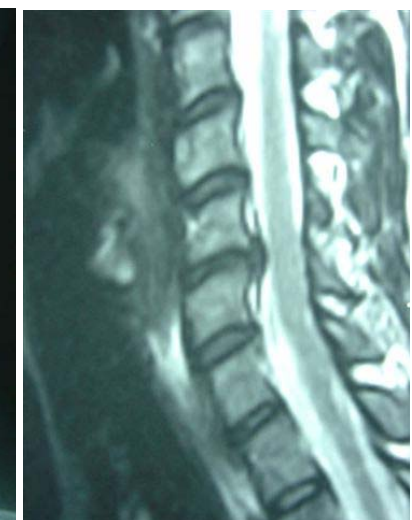

Figure 5

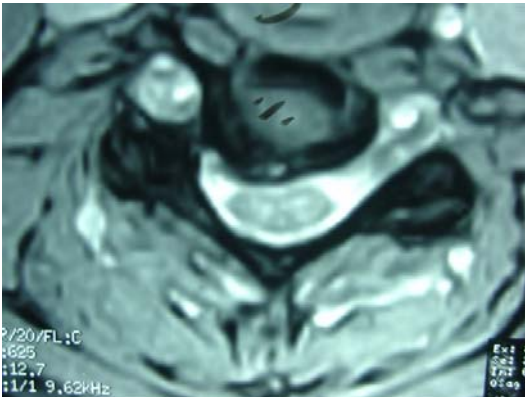


Figure 6

This is a 34 year old female with right arm C6 radiculopathy. The cases correlates instability with disc herniation. See the following figures in sequence of the instability and diagnosis of disc herniation.

Figure 1 shows the alordosis and 6 mm retrolisthesis of C5 on C6.

Figure 2 is extension motion showing no motion of C5 on C6.

Figure 3 is flexion motion showing complete reduction of the C5 retrolisthesis subluxation.

Figure 4 is the oblique view showing sagittal stenosis at the C5-C6 level due to the movement of the superior C6 facet into the osseoligamentous canal.

Figure 5 now shows the large C5-C6 disc herniation.

Figure 6 is the axial view at C5-C6 showing the right large disc herniation with high intensity zones within it. It does contact the spinal cord and narrows the lateral recess at C5-C6.

Two points about this case:

1. It is presented to correlate the instability occurring with the large disc herniation at the C5-C6 level.
2. Cox[®] decompression long y axis distraction procedure resulted in relief of the radiculopathy within three weeks of care. This case was presented at the recent Fort Wayne, Indiana, Part I Certification Course on August 6, 2004.

www.coxtechnic.com